

## Structural brain injury in patients with disorders of consciousness: A voxel-based morphometry study

Pieter Guldenmund, Andrea Soddu, Katherine Baquero, Audrey Vanhauzenhuysse, Marie-Aurélié Bruno, Olivia Gosseries, Steven Laureys & Francisco Gómez

To cite this article: Pieter Guldenmund, Andrea Soddu, Katherine Baquero, Audrey Vanhauzenhuysse, Marie-Aurélié Bruno, Olivia Gosseries, Steven Laureys & Francisco Gómez (2016) Structural brain injury in patients with disorders of consciousness: A voxel-based morphometry study, *Brain Injury*, 30:3, 343-352

To link to this article: <http://dx.doi.org/10.3109/02699052.2015.1118765>



Published online: 18 Feb 2016.



Submit your article to this journal [↗](#)



Article views: 208



View related articles [↗](#)



View Crossmark data [↗](#)



Citing articles: 3 View citing articles [↗](#)

ORIGINAL ARTICLE

## Structural brain injury in patients with disorders of consciousness: A voxel-based morphometry study

Pieter Guldenmund<sup>1</sup>, Andrea Soddu<sup>2</sup>, Katherine Baquero<sup>3,4</sup>, Audrey Vanhauzenhuysse<sup>1,5</sup>, Marie-Aurélié Bruno<sup>1</sup>, Olivia Gosseries<sup>1</sup>, Steven Laureys<sup>1</sup>, & Francisco Gómez<sup>1,6</sup>

<sup>1</sup>Coma Science Group, Cyclotron Research Center and University Hospital of Liège, University of Liège, Liège, Belgium, <sup>2</sup>Brain & Mind Institute, Physics & Astronomy Department, Western University, London, Ontario, Canada, <sup>3</sup>Computer Imaging and Medical Applications Laboratory, National University of Colombia, Bogotá, Colombia, <sup>4</sup>MoVeRe Group, Cyclotron Research Center, University of Liège, Liège, Belgium, <sup>5</sup>Algology-Palliative Care Department, University Hospital of Liège, University of Liège, Liège, Belgium, and <sup>6</sup>Computer Science Department, Central University of Colombia, Bogotá, Colombia

### Abstract

**Main objective:** Disorders of consciousness (DOC; encompassing coma, vegetative state/unresponsive wakefulness syndrome (VS/UWS) and minimally conscious state minus/plus (MCS-/++)) are associated with structural brain injury. The extent of this damage remains poorly understood and merits a detailed examination using novel analysis techniques.

**Research design/methods and procedures:** This study used voxel-based morphometry (VBM) on structural magnetic resonance imaging scans of 61 patients with DOC to examine grey and white matter injury associated with DOC, time spent in DOC, aetiology and diagnosis.

**Main outcomes and results:** DOC and time spent in DOC were found to be associated with widespread structural brain injury, although the latter did not correlate strongly with injury in the right cerebral hemisphere. Traumatic, as compared to non-traumatic aetiology, was related to more injury in the brainstem, midbrain, thalamus, hypothalamus, basal forebrain, cerebellum, and posterior corpus callosum. Potential structural differences were found between VS/UWS and MCS and between MCS- and MCS+, but need further examination.

**Conclusions:** The findings indicate that both traumatic and non-traumatic DOC are associated with widespread structural brain injury, although differences exist that could lead to aetiology-specific treatment strategies. Furthermore, the high degree of atrophy occurring after initial brain injury prompts the development and use of neuroprotective techniques to potentially increase patients' chances of recovery.

### Keywords

Vegetative state/unresponsive wakefulness syndrome, minimally conscious state, structural brain injury, voxel-based morphometry

### History

Received 26 March 2015

Accepted 7 November 2015

Published online 18 February 2016

### Background

Coma can result from severe brain injury and manifests itself as a condition of unconsciousness in which a patient has the eyes closed. It usually lasts no longer than 3 weeks, after which a patient may proceed to a vegetative state/unresponsive wakefulness syndrome (VS/UWS); a state of higher brain arousal, as evidenced by periodic sustained eye opening and unpurposeful movements, but without detectable awareness [1]. A patient may then enter a minimally conscious state (MCS), in which fluctuating and incomplete awareness and arousal is present. The MCS has recently been divided into MCS- and MCS+, with patients in the latter condition showing command following, intelligible verbalization or gestural or verbal yes/no responses to spoken or written questions [2]. These conditions

are collectively known as disorders of consciousness (DOC). In some rare cases, usually due to a lesion in the upper pons, a patient can recover from a coma and become locked-in [3,4]. The locked-in syndrome occurs when a patient has recovered full consciousness, but is extremely limited in communication with the outside world due to (near-)complete body paralysis. The inability of some locked-in patients to move may lead to an incorrect diagnosis when the patients are assessed only with behavioural scales [3].

With the advent of modern brain imaging methods, including positron emission tomography and resting state functional magnetic resonance imaging (resting state fMRI), task-free paradigms have enabled researchers to find patterns of brain activity or structure that can aid in determining whether a patient is conscious (partially (MCS) or completely (locked-in syndrome)) or not (VS/UWS) [5,6]. With task-free neuroimaging, an examiner is not dependent on patient co-operation and a patient's possibility to exhibit body movement. In resting state fMRI, examination of intactness of the default mode network (DMN) might improve diagnosis in DOC, as it is known to be important for internally-oriented consciousness [5,7–12]. In

Correspondance: Pieter Guldenmund and Steven Laureys, Coma Science Group, Cyclotron Research Center, B30, Allée du 6 août, Sart Tilman, 4000 Liège, Belgium. E-mail: [guldenmund@hotmail.com](mailto:guldenmund@hotmail.com); [steven.laureys@ulg.ac.be](mailto:steven.laureys@ulg.ac.be)

Color versions of one or more of the figures in the article can be found online at [www.tandfonline.com/ibij](http://www.tandfonline.com/ibij).

recent years, interest has also increased for other brain regions associated with specific higher-order networks [13]. These include bilateral external control networks (ECN), important for external awareness [7], and the salience network, which has been associated with mounting appropriate responses to salient stimuli [14]. The role of the thalamus in DOC has also been explored. Thalamic metabolism has been shown to be depressed in a way correlating with the level of consciousness, as detected with behavioural examinations [3,15,16]. Interestingly, restoration of thalamocortical connectivity has been associated with recovery of a patient in chronic VS/UWS [17].

Although considerable progress has been made in the comprehension of functional and metabolic activity of the brain and its disturbance in DOC, much uncertainty remains about how to interpret structural brain injury [18]. Injury to the thalamus and brainstem and extensive cerebral injury are among the most frequent observations in DOC in post-mortem [19–26] and MRI studies [25–30]. Equally little is known about brain atrophy secondary to the injury causing DOC [31,32]. This can result from herniations, diffuse cerebral swelling, secondary infarction, haemorrhage and long-term brain inactivity in general [31,33,34]. Another matter of interest is the difference in the pattern of structural brain injury between traumatic and non-traumatic DOC. Traumatic aetiology has been associated with more pronounced brainstem injury [30]. Furthermore, no clear structural differences have been found to distinguish MCS from VS/UWS. In one study [27], thalamic volume was shown to be smaller on average in VS/UWS than in MCS. Global white matter injury, as seen with diffusion tensor imaging, has also been found to possibly discriminate between the patient groups [28]. Lastly, it is unknown whether an assessment of brain structure can discriminate MCS+ from MCS– in a similar way as has been shown for positron emission tomography-based assessment of brain metabolism, indicating more severe injury in the left cerebral cortex in MCS– [35]. A recent diffusion tensor imaging study has furthermore provided evidence of a role for the thalamus and posterior cingulate cortex/precuneus [29].

The present study provides new and potentially clinically relevant insights into structural brain injury in patients with DOC. This study describes grey and white matter volume decreases of 61 patients with DOC, using voxel-based morphometry (VBM) [36,37], and interprets these volume decreases as structural brain injury. We examined five aspects, namely: (1) structural brain injury associated with DOC; (2) the effect of time spent in DOC on brain grey and white matter integrity; (3) aetiology-based differences in structural brain injury; (4) differences between VS/UWS and MCS; (5) differences between patients in MCS– and MCS+. Given the results from previous studies, widespread structural brain injury was expected in patients with DOC [20–24,27,38], which might become more severe with increasing time spent in DOC [31,34,39–41]. Patients with DOC with a traumatic aetiology, as compared to those with a non-traumatic aetiology, might have more focal injury centred on regions that are especially susceptible to acceleration, deceleration, and rotational forces often experienced in trauma and near rough skull edges. These regions include the brainstem, thalamus, hypothalamus, cerebellum and basal fore-brain [30,42–44]. Differences between VS/UWS and MCS might be more global than focal, based on the absence of clear

structural differences mentioned in the literature [28], although thalamic injury might have especially high discriminatory power [27]. Given the found importance of the DMN and especially the posterior cingulate cortex/precuneus in previous neuroimaging studies [3,5,29,45], more injury was expected in DMN regions in patients in VS/UWS. Based on a previous metabolic study, which found the left cerebral cortex more affected in MCS– as compared to MCS+, structural integrity differences were anticipated in the left cerebral cortex, most often associated with language functions, between MCS– and MCS+ [35].

## Methods

### Subjects and data acquisition

For this analysis, T1 structural magnetic resonance images acquired on a 3T scanner (Siemens AG, Munich, Germany) were used; TR = 2300 ms, TE = 2.47 ms, T1-weighted 3D gradient echo images with  $1 \times 1 \times 1.2 \text{ mm}^3$  voxels in the sagittal plane, flip angle =  $9^\circ$ , matrix size =  $256 \times 240 \times 144 \text{ mm}^3$ , field of view = 256 mm) of 34 patients in VS/UWS, 62 patients in MCS, and 28 healthy control subjects. The study was approved by the Ethics Committee of the Medical School of the University of Liège. Informed consent to participate in the study was obtained from the subjects themselves in the case of healthy subjects and from the legal surrogate of the patients. Diagnosis was based on daily behavioural analysis with the Coma Recovery Scale Revised (CRS-R) during the period of a week, in which the highest CRS-R sub- and total scores were considered decisive (Table I) [46]. The CRS-R is a standardized behavioural scale that is currently considered to be the best behavioural diagnosis tool for patients with DOC available and is, therefore, used in most DOC neuroimaging studies as a behavioural diagnosis reference point [47,48]. Of this initial group, 18 patients in VS/UWS (mean age = 40, SD = 19 years; 12 traumatic; mean time spent in DOC = 1230, SD = 1818 days) and 17 patients in MCS (mean age = 39, SD = 20 years; 7 traumatic; mean time spent in DOC = 1443, SD = 2699 days) were excluded from further analysis due to large haemorrhage effects, movement artifacts, foreign body artifacts, midline shifts, acquisition artifacts, low grey-white matter contrast or exceptionally large structural brain injury visible on the initial T1 images; as assessed by careful visual inspection of the T1 images by an expert who was blinded to the patients' diagnoses. This step, which introduced a bias into the analysis, was done in an effort to minimize the chance of severe segmentation and normalization problems occurring during the VBM procedure [29,36,49–51]. Visual inspection of VBM segmentation and normalization results performed to examine VBM performance did not lead to further rejection of patient data. Following the exclusions, data were used from 16 patients in VS/UWS, 45 patients in MCS and 28 control subjects (Tables I and II).

### Pre-processing

T1 structural images were automatically re-oriented before pre-processing with software from the VBM8 toolbox (<http://dbm.neuro.uni-jena.de/vbm/>) for SPM8 ([www.fil.ion.ucl.ac.uk/spm/](http://www.fil.ion.ucl.ac.uk/spm/)). A warping regularization of 4 was selected, instead of the

Table I. Patient data.

Subj.	Diagnosis according to CRS-R	CRS-R highest total score (and sub-scores*)	Aetiology	Age at onset (in years)	Time spent in DOC (in days)
1	VS/UWS	6 (1,0,2,2,0,1)	n-T (anoxia)	73	92
2	VS/UWS	6 (1,0,2,1,0,2)	n-T (CVA)	62	32
3	VS/UWS	3 (0,0,1,1,0,1)	n-T (anoxia)	44	22
4	VS/UWS	3 (0,0,2,1,0,0)	n-T (CVA)	73	7
5	VS/UWS	6 (1,0,1,2,0,2)	T	16	615
6	VS/UWS	7 (1,0,2,2,0,2)	T	21	196
7	VS/UWS	5 (1,0,2,1,0,1)	n-T (metabolic disorder)	53	20
8	VS/UWS	5 (1,1,1,1,0,1)	n-T (CVA)	63	32
9	VS/UWS	5 (1,0,1,1,0,2)	n-T (anoxia)	48	52
10	VS/UWS	5 (0,0,2,1,0,2)	n-T (CVA)	56	26
11	VS/UWS	6 (1,0,1,2,0,2)	n-T (anoxia)	42	104
12	VS/UWS	4 (1,0,1,0,0,2)	n-T (anoxia)	44	27
13	VS/UWS	7 (1,1,2,1,0,2)	n-T (CVA)	74	40
14	VS/UWS	5 (1,0,1,1,0,2)	n-T (anoxia)	16	27
15	VS/UWS	5 (1,0,2,1,0,1)	n-T (anoxia)	69	50
16	VS/UWS	6 (1,0,1,2,0,2)	n-T (anoxia)	31	456
17	MCS	7 (0,3,1,2,0,1)	T	30	569
18	MCS	13 (1,3,5,2,0,2)	n-T (anoxia)	30	1188
19	MCS	8 (1,3,2,0,0,2)	n-T (CVA)	59	21
20	MCS	10 (1,3,2,2,0,2)	T	19	905
21	MCS	10 (1,3,2,2,0,2)	n-T (CVA)	33	1869
22	MCS	9 (1,3,2,2,0,1)	n-T (anoxia)	50	68
23	MCS	9 (0,3,2,2,0,2)	T	34	3139
24	MCS	9 (1,3,2,1,0,2)	n-T (anoxia)	39	17
25	MCS	13 (3,5,2,0,1,2)	T	45	533
26	MCS	11 (3,3,2,1,0,2)	T	23	752
27	MCS	8 (3,1,1,1,0,2)	n-T (CVA)	64	1383
28	MCS	12 (3,3,2,2,0,2)	T	26	3034
29	MCS	15 (3,3,5,1,1,2)	T	22	3226
30	MCS	9 (3,0,2,2,0,2)	T/n-T (trauma + anoxia)	23	1538
31	MCS	12 (3,3,3,2,0,1)	T	30	583
32	MCS	5 (1,0,1,1,1,1)	n-T (CVA)	74	18
33	MCS	14 (3,5,0,3,1,2)	n-T (epilepsy)	52	20
34	MCS	11 (3,3,3,1,0,1)	n-T (CVA)	70	11
35	MCS	12 (3,4,2,1,0,2)	T	65	22
36	MCS	11 (3,3,2,1,0,2)	T	30	145
37	MCS	11 (3,2,5,0,0,1)	T	22	38
38	MCS	10 (3,3,0,2,0,2)	n-T (CVA)	39	37
39	MCS	13 (3,3,5,0,0,2)	T/n-T (trauma + anoxia)	17	2690
40	MCS	17 (3,4,5,2,1,2)	T/n-T (trauma + anoxia)	29	400
41	MCS	7 (3,0,2,1,0,1)	T/n-T (trauma + anoxia)	25	314
42	MCS	14 (3,5,3,1,0,2)	T	36	342
43	MCS	15 (4,5,2,0,1,3)	n-T (CVA)	87	7
44	MCS	13 (3,3,3,1,1,2)	T	22	421
45	MCS	12 (1,3,3,2,1,2)	n-T (metabolic disorder)	48	64
46	MCS	7 (4,2,0,0,0,1)	n-T (CVA)	64	7
47	MCS	18 (3,5,5,3,1,1)	T	60	51
48	MCS	7 (3,0,2,1,0,1)	T	13	257
49	MCS	16 (3,5,5,1,0,2)	T	22	1157
50	MCS	11 (0^,3,5,1,0,2)	n-T (anoxia)	72	5
51	MCS	16 (3,4,5,2,0,2)	T	54	202
52	MCS	10 (3,3,1,1,0,2)	T	17	1333
53	MCS	16 (3,3,5,2,0,3)	n-T (metabolic disorder)	54	311
54	MCS	8 (3,0,2,1,0,2)	T	31	1331
55	MCS	14 (3,3,5,2,0,1)	n-T (CVA)	71	22
56	MCS	11 (3,0,3,3,1,1)	n-T (CVA)	66	37
57	MCS	11 (3,3,2,1,0,2)	T	19	219
58	MCS	13 (3,5,2,1,0,2)	T	21	3342
59	MCS	15 (3,3,5,1,1,2)	T	45	3216
60	MCS	11 (3,3,2,1,0,2)	T	36	134
61	MCS	7 (3,0,1,2,0,1)	T	64	677

CVA, cerebrovascular accident; T, traumatic; n-T, non-traumatic; Subj., subject number.

^ A value of 3 has been obtained during another CRS-R assessment.

\* CRS-R sub-scores are, in the following order: auditory, visual, motor, verbal, communication, arousal.

Table II. Summary of patient data.

Group	Size	Mean age (onset), years	Mean age (scan), years	Mean time spent in DOC, days	Range of time spent in DOC, days	Aetiology	Mean CRS-R score	Sex
VS/ UWS	16	49 (SD = 20)	49 (SD = 20)	112 (SD = 174)	7 – 615	2 traumatic	5 (SD = 1)	6 females
MCS	45	41 (SD = 19)	43 (SD = 19)	792 (SD = 1041)	5 – 3342	28 traumatic	11 (SD = 3)	14 females
Controls	28	—	48 (SD = 17)	—	—	—	—	13 females

VBM8 standard 1, to mildly reduce the chance of unrealistic deformations occurring. The sampling distance was put at 1 mm, instead of the VBM8 standard of 4 mm, to increase the amount of structural data used and, thus, VBM8 accuracy (<http://dbm.neuro.uni-jena.de/vbm/>). Spatial normalization was performed using DARTEL [51], to allow for high-dimensional spatial normalization to increase the chance of correct normalization in the severely injured DOC brain [52]. Furthermore, this study used a DARTEL-based method implemented in VBM8 to construct a DOC template made from T1 images of this DOC population to use in the DARTEL-based normalization procedure for the DOC and control groups [51,53]. This template was used to minimize the chance of normalization problems occurring [18,37], since it minimized the degree of warping necessary for DOC brains in the normalization step, thus potentially decreasing the chance of misclassification and normalization errors occurring during the VBM process [53]. For de-noising purposes, a VBM8-incorporated spatial adaptive non-local means de-noising filter [54] and Markov random field weighting [55], put at 0.15, were used. After segmentation, the images were modulated (the automatic multiplication of voxel values by the deformity parameters calculated during the normalization process) to compensate for the deformity that occurs in normalization, preserving the white and grey matter volumes considered in this analysis. As advised by the authors of VBM8, only non-linear images were written, which corrects for differences in total grey matter volume. After VBM pre-processing, resulting grey and white matter segments were smoothed with a 12 mm kernel. As the morphology of DOC brains is more challenging for VBM than that of controls, this larger kernel size was used rather than a more commonly employed 8 mm smoothing kernel in an effort to minimize the occurrence of possible false positive results. These could have resulted from problems in the normal distribution of error terms in the statistical model used by VBM8 to construct parametric statistical tests [50,56,57]. Furthermore, it helped to better minimize the influence of noise [58] and the effect of individual differences in gyral anatomy [59]. A limitation of using bigger smoothing kernels is a loss of spatial detail [56]. The smoothed images were used for a statistical analysis with SPM8.

### Statistical analysis

Five main analyses were performed to examine the structural brain injury associated with DOC, brain atrophy correlating with the time spent in DOC, differences in structural brain

injury between traumatic and non-traumatic aetiologies, differences between VS/UWS- and MCS-related injury and differences in structural brain injury between MCS- and MCS+. First, the whole group of patients with DOC was contrasted against healthy control subjects. These groups were matched for age.

Second, the effect of time spent in DOC on brain atrophy for a DOC group consisting of all patients in VS/UWS and MCS was assessed. These groups were matched for age. The time a patient spent in the DOC at the day of scanning was used as a covariate (the natural logarithm of the time spent in DOC in days was used; the natural logarithm was chosen, as, given known biological secondary responses to primary brain injury [33,60–62], the effect of time on structural brain injury was expected to be strongest in the initial weeks). The structural brain injury correlating to this covariate was examined.

Third, a direct comparison between structural brain injury in traumatic and non-traumatic patients with DOC (VS/UWS and MCS combined) was performed using a two-sample *t*-test. Of the initial DOC group, patients with outlier values or mixed aetiology (10 traumatic, mean age = 22 years, SD = 8 years; 13 non-traumatic, mean age = 70 years, SD = 7 years; four mixed aetiology, mean age = 24 years, SD = 5 years) were excluded from the analysis to make matching of age and time spent in DOC possible for the remaining patients. The resulting DOC group consisted of 16 traumatic (mean age = 38 years, SD = 15 years) and 18 non-traumatic patients (mean age = 45 years, SD = 12 years).

Fourth, potential differences in structural brain injury between VS/UWS and MCS were examined. For this, to remove a potential aetiology effect, only the 31 non-traumatic patients in DOC were used, and the four patients with mixed aetiology (mean age = 24 years, SD = 5 years) and 26 patients with traumatic aetiology (mean age = 32 years, SD = 15 years) were excluded, as only two patients in VS/UWS in the original dataset were traumatic. Fourteen patients in VS/UWS (mean age = 53 years, SD = 17 years) and 17 patients in MCS (mean age = 57 years, SD = 16 years), matched for age and time spent in DOC, were included in the analysis. A two-sample *t*-test examined structural brain injury differences between VS/UWS and MCS. This study used a DMN spatial map constructed from resting state fMRI data from 20 healthy subjects (mean age = 47 years, SD = 18 years), which was comparable to the DMN as reported in literature [63], to mask out non-DMN regions. Differences between non-traumatic patients in VS/UWS and patients in MCS that occurred in DMN regions and survived a *p*-value threshold of 0.01

(uncorrected) and voxel extent threshold of 30 were also examined [64].

Fifth, the full group of patients in MCS (eight in MCS-, mean age = 37 years, SD = 13 years; 37 in MCS+, mean age = 42 years, SD = 21 years) were used, matched for age and time spent in DOC, to examine the potential structural differences between patients in MCS- and those in MCS+. This study accepted results surviving a  $p$ -value threshold of 0.01 (uncorrected) and voxel extent threshold of 30, given the *a priori* knowledge [35].

## Results

DOC was associated with widespread grey and white matter injury (Figure 1). Similarly, widespread atrophy was found to correlate with time spent in DOC, with a relative sparing of the right cortical hemisphere (Figure 2). Comparison between the traumatic and the non-traumatic patient groups showed that, in traumatic patients, more structural brain injury was found in the lower thalamus/midbrain ( $x = 0, y = -22, z = -2$ ), hypothalamus ( $x = 0, y = -3, z = -5$ ), basal forebrain ( $x = -6, y = 20, z = -5$ ), cerebellum ( $x = 3, y = -52, z = -21$ ), brainstem ( $x = -2, y = -39, z = -9$ ) and posterior corpus callosum ( $x = 0, y = -30, z = 21$ ) (Figure 3). No differences in grey or white matter injury were found between patients in VS/UWS and patients in MCS, as seen when using a threshold of false discovery rate-corrected  $p = 0.05$ . However, using an inclusive spatial DMN mask and a more liberal threshold of  $p = 0.01$  (uncorrected), more injury was detected in patients in VS/UWS in the ventromedial prefrontal cortex ( $x = 14, y = 50, z = -9$ ) and the posterior cingulate cortex/precuneus ( $x = -15, y = -61, z = 18$ ) when contrasting VS/UWS and MCS (Figure 4). Contrasting patients in MCS- with those in MCS+, using a liberal threshold of  $p = 0.01$  (uncorrected), it was found that patients in MCS+ had a more preserved left cerebral cortex, including the middle temporal gyrus (multimodal posterior area,  $x = -68, y = -55, z = 0$ ), superior temporal gyrus (primary auditory cortex,  $x = -69, y = -22, z = 9$ ; and Wernicke's area,  $x = -66, y = -37, z = 16$ ) and inferior frontal gyrus (Broca's area,  $x = -57, y = 24, z = 16$ ) (Figure 5).

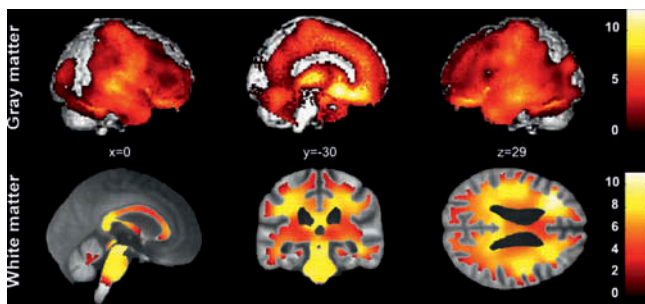


Figure 1. Gray matter (top) and white matter (bottom) injury associated with DOC in 61 patients (false discovery rate-corrected at  $p = 0.05$ ). White matter results were superimposed on an averaged T1 that was calculated from all normalized T1's of the DOC group. The color bars represent T-values.

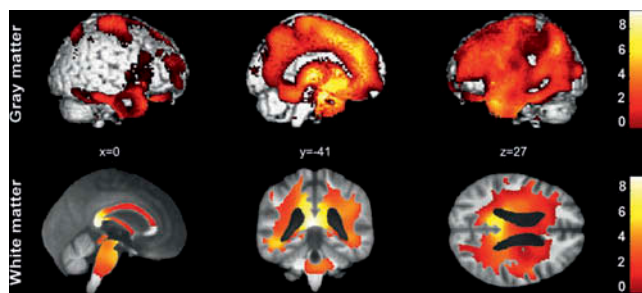


Figure 2. Gray matter (top) and white matter (bottom) atrophy associated with time spent in DOC (false discovery rate-corrected at  $p = 0.05$ ) in 61 patients with DOC. White matter results were superimposed on an averaged T1 that was calculated from all normalized T1's of the DOC group. The color bars represent T-values.

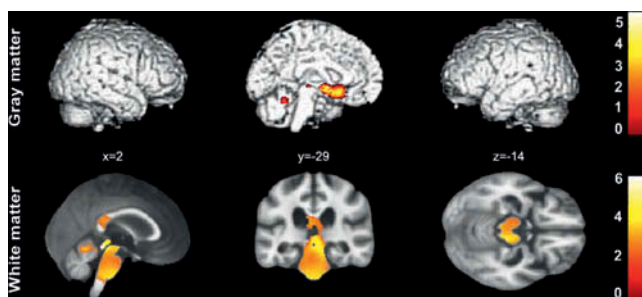


Figure 3. Gray matter (top) and white matter (bottom) injury more evident in traumatic than in non-traumatic DOC (false discovery rate-corrected at  $p = 0.05$ ) in a group (VS/UWS and MCS combined) of 16 traumatic and 18 non-traumatic patients, matched for age and time spent in DOC. White matter results were superimposed on an averaged T1 that was calculated from all normalized T1's of the DOC group. The color bars represent T-values.

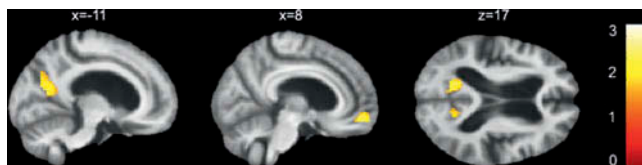


Figure 4. Regions of the bilateral posterior cingulate cortex/precuneus and ventromedial prefrontal cortex appear to be more injured in non-traumatic VS/UWS as compared to non-traumatic MCS. The groups of 14 patients in VS/UWS and 17 patients in MCS were matched for age and time spent in DOC. Results were thresholded at  $p = 0.05$  (uncorrected) for display purposes and superimposed on an averaged T1 that was calculated from all normalized T1's of the DOC group. An inclusive DMN mask was used. The color bar represents T-values.

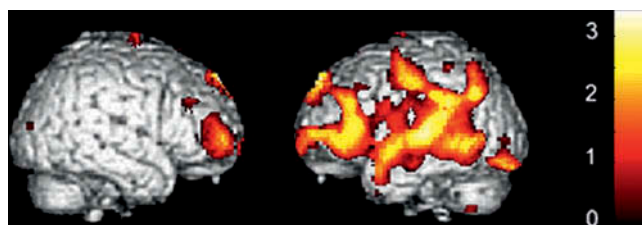


Figure 5. The left cerebral cortex was found to be more injured in MCSminus as compared to MCSplus. The groups of 8 patients in MCSminus and 37 patients in MCSplus were matched for age and time spent in DOC. Results were thresholded at  $p = 0.05$  (uncorrected) for display purposes. The color bar represents T-values.

## Discussion

### Methodological considerations

VBM, based on DARTEL, is an established and widely used technique to assess differences in brain structure and has been shown to operate well in cases of relatively mild-to-severe structural brain injury [65,66]. In many cases, structural brain injury in patients with DOC belongs to the most severe class of structural brain injury, with brains often showing great morphological changes like ventricle enlargement [65]. Therefore, to minimize the chance of false results, a smoothing kernel of 12 mm was used and a patient specific DARTEL template was employed [67]. Patients with large haemorrhage effects, movement artifacts, foreign body artifacts, midline shifts, acquisition artifacts, low grey-white matter contrast or exceptionally large structural brain injury, were also excluded. This way, data from 35 patients were discarded. This high exclusion rate introduced a bias into the examination, which was regarded as being necessary in order to obtain successful segmentation and normalization [36,51]. The view is that further research into DOC brain morphology and VBM methods should be performed before brain scans with the above-mentioned rejection criteria could be included. Future studies might also include more patients than the present study, to make analysis of interactions between variables possible. For the analysis of the effect of time spent in DOC on brain morphology, we were limited by the dataset, since there were only MRI scans acquired during one time point. A two time point design would have been more suited to examining the atrophy correlating with time spent in DOC. Fortunately, given the large number of patients included, inferences could still be made upon this effect. However, it is important to acknowledge that the unavailability of information about the severity of the lesions of the chronic patients in the acute stage might have introduced a bias. The results from the analyses of differences between structural brain injury in VS/UWS and MCS, as well as between MCS– and MCS +, did not survive whole brain false discovery rate correction. At a threshold of  $p = 0.01$  (uncorrected), there is a realistic chance of false positive results. It should, furthermore, be noted that, in the analysis of the effect of aetiology, in order to match age and time spent in DOC between groups, a substantial number of patients was excluded. Similarly, exclusion was necessary for the comparison between VS/UWS and MCS. This might have introduced a bias. Nonetheless, although future studies should aim to replicate these results, the findings are strengthened by previous neuroimaging studies. Finally, VBM8 was developed mainly for examination of grey matter. However, a growing number of studies have also used VBM for non-diffusion tensor imaging-based examination of white matter [52,68–70]. Therefore, although extra restraint might be advisable in its interpretation, this study included the VBM-based white matter examinations.

### Structural brain injury associated with DOC

DOC was found to be associated with widespread white and grey matter injury; consistent with findings from previous post-mortem [19–24] and MRI studies [18,27–30]. Detectability of consciousness with behavioural examinations, such as the CRS-R [46–48], is dependent on at least three different factors: brain arousal, internal and external awareness (perception), and the

possibility to mount an appropriate response [71]. Each one of these factors can be influenced by the widespread injury that was found to be associated with DOC. The results emphasize the limits of consciousness detection using behavioural examinations and the need for complementary neuroimaging in the diagnostic process [47,72].

### Time spent in DOC

The time spent in DOC correlated with widespread grey and white matter atrophy. Secondary structural brain injury could influence the potential for patient recovery [32]. Unfortunately, not much is known about its mechanisms and, therefore, ways to interfere with the degradative process. When brain tissue gets injured, a whole cascade of molecular processes takes place, possibly aided by long-time brain inactivity [31,33], leading to events such as inflammation, apoptosis and necrosis in the neighbourhood of the primary injury [24,34,38,73–75]. The potential effectiveness of drugs that are currently used with the aim of improving patient recovery chances in the short- and long-term, such as Amantadine and Baclofen, is subject of continuing research [76,77].

An interesting aspect is the fact that the grey matter atrophy associated with time spent in DOC appeared to be mostly left lateralized. Left lateralized atrophy correlating with time spent in DOC has been previously described [78] and makes an association with severely impaired language processing tentative [78,79]. A recent report also described left lateralized metabolic impairment as a pivotal discriminator between MCS– (i.e. patients only showing non-reflex behaviour such as visual pursuit, localization of noxious stimulation and/or contingent behaviour) and MCS+ (i.e. patients showing comprehension of language) [35]. Future research should indicate whether this left lateralized atrophy might perhaps be associated with long-term inactivity in language systems during DOC and how this could relate to detection of consciousness.

### Aetiology-related injury

We found that the group of traumatic patients with DOC had more injury in the thalamus/midbrain, pons, hypothalamus, basal forebrain and cerebellum, as compared to the group of non-traumatic patients with DOC. Traumatic insults that include rapid deceleration or acceleration cause the brain to move against the skull. As the bottom of the skull has many protuberances, fierce contact might result in injury to the hypothalamus, pituitary, cerebellum and pons [19,42–44]. Furthermore, the brainstem has less movement freedom than the higher lying parts of the brain, which results from the fact that it is connected to the base of the skull. Therefore, rotational shearing injury might occur at the upper brainstem, thalamus and corpus callosum [26,80]. Specific vulnerability of the brainstem in patients with DOC with traumatic aetiologies has previously been found in a diffusion tensor imaging study [30]. This study did not find regions that were more injured in non-traumatic cases. However, it must be noted that such injury may be more widespread and, therefore, potentially more difficult to detect using traditional statistical methods in VBM8. Eventually, the found differences between

aetiologies might lead to aetiology-specific treatment strategies.

The findings show that both traumatic and non-traumatic patients with DOC have widespread injury in white and grey matter. This is in line with previous reports of severe brain injury [81]. Traumatic brain insult can lead to injury in both grey and white matter by application of severe physical pressure on neuronal cell bodies and axons, leading to disrupted cell integrity, such as rupture and shearing. Axonal injury can lead to Wallerian degeneration and related processes [82], while severe white matter disturbance can also include injury to non-neuronal cells that support axonal and synaptic functioning, thereby affecting axon survival [81]. Non-traumatic insults can lead to structural brain injury via disruption of metabolic needs or other vital cell mechanisms in both grey and white matter [81].

### VS/UWS vs MCS

This study did not yield structural differences between VS/UWS and MCS when correcting results for multiple comparisons. The fact that no strong differences between VS/UWS and MCS could be found in a large group of 31 non-traumatic patients, using the latest methods for examining T1 scans in a voxel-wise manner, illustrates the difficulty of differential DOC diagnosis based on structural imaging alone. This problem is emphasized when downscaling to the single subject level. It could be that conventional MRI T1 sequences cannot fully detect certain types of injury, such as more diffuse injury, that could potentially distinguish between VS/UWS and MCS. Such injury might impede whole brain information integration, while islands of cognitive processing, as reported in literature, might still function [83]. Literature on potential structural differences between VS/UWS and MCS is scarce, and the problem of finding robust differences between VS/UWS and MCS at the single subject level also exists for other neuroimaging modalities, such as resting state fMRI and positron emission tomography [3,5,35].

However, at the group level and without correcting for multiple comparisons, the finding of the posterior cingulate cortex/precuneus and ventromedial prefrontal cortex, pivotal DMN regions, as potential discriminators is in line with earlier structural, functional and metabolic neuroimaging reports. A diffusion tensor imaging-based study showed that DMN integrity might discriminate between VS/UWS and MCS [29], while measuring metabolism and connectivity in DMN-related areas, and especially the posterior cingulate cortex/precuneus, also holds promise [3,5,12]. Future studies should aim to find structural, functional and metabolic biomarkers that could, preferably in a multimodal setup, improve diagnosis at the single subject level.

### MCS- vs MCS+

Although differences between MCS- and MCS+ were found at a statistically liberal threshold, *a priori* knowledge strengthened the findings of a more severely disrupted left hemisphere of the cerebral cortex in MCS- as compared to MCS+: higher metabolic dysfunction in the left cerebral hemisphere in patients in MCS- as compared to those in MCS+ has previously been reported [35]. This could be explained by the fact that most patients were right-handed and where language-related processing was, thus, most often associated with the left cerebral

cortex [79]. An understanding of language is of great importance for successfully conducting command following, intelligible verbalization and answering verbal and written questions; the behavioural discriminators between MCS- and MCS+ [35,47]. Thus, the finding of greater injury in MCS- in Wernicke's area, Broca's area, the primary auditory cortex and the multimodal posterior area might be associated with disrupted language processing [84–86].

### Conclusions

Our results show that reduced consciousness in DOC correlates with widespread structural brain injury. Traumatic aetiology was found to be related to more severe focal injury in regions especially vulnerable to head impact-related brain movement. The results, furthermore, show the great extent of atrophy secondary to initial brain injury, with a relative sparing of the right cerebral hemisphere. No clear differences in structural brain injury were found between VS/UWS and MCS in the large patient sample, although a potential discriminator might be the posterior cingulate cortex/precuneus. In line with previous neuroimaging findings, the findings illustrate the difficulty of using only structural MRI for differentiating between VS/UWS and MCS, especially at the single subject level. Finally, a liberal threshold indicated that patients in MCS+ are likely to have a more preserved left cerebral cortex than patients in MCS-, which could be linked to the language functions most frequently attributed to this cerebral hemisphere.

### Declaration of interest

This research was funded by the Belgian National Funds for Scientific Research (Brussels, Belgium), the European Commission (Brussels, Belgium), the James McDonnell Foundation (Saint Louis, MO, USA), the Mind Science Foundation (San Antonio, TX, USA), the French Speaking Community Concerted Research Action (ARC, 06/11-340, Brussels, Belgium), the Fondation Médicale Reine Elisabeth (Brussels, Belgium), the University of Liège (Liège, Belgium) and the University Hospital of Liège (Liège, Belgium). The authors report no conflicts of interest. The authors alone are responsible for the content and writing of the paper.

### References

1. Laureys S, Celesia GG, Cohadon F, Lavrijsen J, Leon-Carrion J, Sannita WG, Szabon L, Schmutzhard E, von Wild KR, Zeman A, et al. Unresponsive wakefulness syndrome: a new name for the vegetative state or apallic syndrome. *BMC Medicine* 2010;8:68.
2. Bruno MA, Vanhaudenhuyse A, Thibaut A, Moonen G, Laureys S. From unresponsive wakefulness to minimally conscious PLUS and functional locked-in syndromes: recent advances in our understanding of disorders of consciousness. *Journal of Neurology* 2011;258:1373–1384.
3. Laureys S, Owen AM, Schiff ND. Brain function in coma, vegetative state, and related disorders. *Lancet Neurology* 2004;3:537–546.
4. Laureys S, Pellas F, Van Eeckhout P, Ghorbel S, Schnakers C, Perrin F, Berre J, Faymonville ME, Pantke KH, Damas F, et al. The locked-in syndrome: what is it like to be conscious but paralyzed and voiceless? *Progress Brain Research* 2005;150:495–511.
5. Vanhaudenhuyse A, Noirhomme Q, Tshibanda LJ, Bruno MA, Boveroux P, Schnakers C, Soddu A, Perlberg V, Ledoux D,



- Brichant JF, et al. Default network connectivity reflects the level of consciousness in non-communicative brain-damaged patients. *Brain* 2010;133:161–171.
6. Phillips CL, Bruno MA, Maquet P, Boly M, Noirhomme Q, Schnakers C, Vanhaudenhuyse A, Bonjean M, Hustinx R, Moonen G, et al. 'Relevance vector machine' consciousness classifier applied to cerebral metabolism of vegetative and locked-in patients. *Neuroimage* 2011;56:797–808.
  7. Vanhaudenhuyse A, Demertzi A, Schabus M, Noirhomme Q, Bredart S, Boly M, Phillips C, Soddu A, Luxen A, Moonen G, et al. Two distinct neuronal networks mediate the awareness of environment and of self. *Journal of Cognitive Neuroscience* 2011;23:570–578.
  8. Sharp DJ, Beckmann CF, Greenwood R, Kinnunen KM, Bonnelle V, De Boissezon X, Powell JH, Counsell SJ, Patel MC, Leech R. Default mode network functional and structural connectivity after traumatic brain injury. *Brain* 2011;134:2233–2247.
  9. Guldenmund P, Vanhaudenhuyse A, Boly M, Laureys S, Soddu A. A default mode of brain function in altered states of consciousness. *Archives Italiennes de Biologie* 2012;150:107–121.
  10. Boveroux P, Vanhaudenhuyse A, Bruno MA, Noirhomme Q, Lauwick S, Luxen A, Degueldre C, Plenevaux A, Schnakers C, Phillips C, et al. Breakdown of within- and between-network resting state functional magnetic resonance imaging connectivity during propofol-induced loss of consciousness. *Anesthesiology* 2010;113:1038–1053.
  11. Guldenmund P, Demertzi A, Boveroux P, Boly M, Vanhaudenhuyse A, Bruno MA, Noirhomme Q, Brichant JF, Bonhomme V, Laureys S, et al. Thalamic, brainstem and salience network connectivity changes during mild propofol sedation and unconsciousness. *Brain Connect* 2013;3:273–285.
  12. Crone JS, Soddu A, Holler Y, Vanhaudenhuyse A, Schurz M, Bergmann J, Schmid E, Trinka E, Laureys S, Kronbichler M. Altered network properties of the fronto-parietal network and the thalamus in impaired consciousness. *Neuroimage: Clinical* 2013;4:240–248.
  13. Heine L, Soddu A, Gomez F, Vanhaudenhuyse A, Tshibanda L, Thonnard M, Charland-Verville V, Kirsch M, Laureys S, Demertzi A. Resting state networks and consciousness: alterations of multiple resting state network connectivity in physiological, pharmacological, and pathological consciousness States. *Frontiers in Psychology* 2012;3:295.
  14. Menon V, Uddin LQ. Saliency, switching, attention and control: a network model of insula function. *Brain Structure and Function* 2010;214:655–667.
  15. Lull N, Noe E, Lull JJ, Garcia-Panach J, Chirivella J, Ferri J, Lopez-Aznar D, Sopena P, Robles M. Voxel-based statistical analysis of thalamic glucose metabolism in traumatic brain injury: relationship with consciousness and cognition. *Brain Injury* 2010;24:1098–1107.
  16. Lull N, Noe E, Lull JJ, Garcia-Panach J, Garcia-Marti G, Chirivella J, Ferri J, Sopena R, de La Cueva L, Robles M. [Thalamic metabolism and neurological outcome after traumatic brain injury. A voxel-based morphometric FDG-PET study]. *Neurologia* 2010;25:174–180.
  17. Laureys S, Faymonville ME, Luxen A, Lamy M, Franck G, Maquet P. Restoration of thalamocortical connectivity after recovery from persistent vegetative state. *Lancet* 2000;355:1790–1791.
  18. Juengling FD, Kassubek J, Huppertz HJ, Krause T, Els T. Separating functional and structural damage in persistent vegetative state using combined voxel-based analysis of 3-D MRI and FDG-PET. *Journal of Neurological Sciences* 200;228:179–184.
  19. Jellinger KA. Neuropathology of prolonged unresponsive wakefulness syndrome after blunt head injury: Review of 100 post-mortem cases. *Brain Injury* 2013;27:917–923.
  20. Kinney HC, Korein J, Panigrahy A, Dikkes P, Goode R. Neuropathological findings in the brain of Karen Ann Quinlan. The role of the thalamus in the persistent vegetative state. *New England Journal of Medicine* 1994;330:1469–1475.
  21. Adams JH, Graham DI, Jennett B. The neuropathology of the vegetative state after an acute brain insult. *Brain* 2000;123:1327–1338.
  22. Adams JH, Jennett B, McLellan DR, Murray LS, Graham DI. The neuropathology of the vegetative state after head injury. *Journal of Clinical Pathology* 1999;52:804–806.
  23. Maxwell WL, Pennington K, MacKinnon MA, Smith DH, McIntosh TK, Wilson JT, Graham DI. Differential responses in three thalamic nuclei in moderately disabled, severely disabled and vegetative patients after blunt head injury. *Brain* 2004;127:2470–2478.
  24. Maxwell WL, MacKinnon MA, Smith DH, McIntosh TK, Graham DI. Thalamic nuclei after human blunt head injury. *Journal of Neuropathology & Experimental Neurology* 2006;65:478–488.
  25. Rosenblum WI. Immediate, irreversible, posttraumatic coma: a review indicating that bilateral brainstem injury rather than widespread hemispheric damage is essential for its production. *Journal of Neuropathology & Experimental Neurology* 2015;74:198–202.
  26. Edlow BL, Haynes RL, Takahashi E, Klein JP, Cummings P, Benner T, Greer DM, Greenberg SM, Wu O, Kinney HC, et al. Disconnection of the Ascending Arousal System in Traumatic Coma. *Journal of Neuropathology & Experimental Neurology* 2013;72:505–523.
  27. Fernandez-Espejo D, Junque C, Bernabeu M, Roig-Rovira T, Vendrell P, Mercader JM. Reductions of thalamic volume and regional shape changes in the vegetative and the minimally conscious states. *Journal of Neurotrauma* 2010;27:1187–1193.
  28. Fernandez-Espejo D, Bekinschtein T, Monti MM, Pickard JD, Junque C, Coleman MR, Owen AM. Diffusion weighted imaging distinguishes the vegetative state from the minimally conscious state. *Neuroimage* 2011;54:103–112.
  29. Fernandez-Espejo D, Soddu A, Cruse D, Palacios EM, Junque C, Vanhaudenhuyse A, Rivas E, Newcombe V, Menon DK, Pickard JD, et al. A role for the default mode network in the bases of disorders of consciousness. *Annals of Neurology* 2012;72:335–343.
  30. Newcombe VF, Williams GB, Scoffings D, Cross J, Carpenter TA, Pickard JD, Menon DK. Aetiological differences in neuroanatomy of the vegetative state: insights from diffusion tensor imaging and functional implications. *Journal of Neurology, Neurosurgery & Psychiatry* 2010;81:552–561.
  31. Rousseau MC, Confort-Gouy S, Catala A, Graperon J, Blaya J, Soulier E, Viout P, Galanaud D, Le Fur Y, Cozzone PJ, et al. A MRS-MRI-fMRI exploration of the brain. Impact of long-lasting persistent vegetative state. *Brain Injury* 2008;22:123–134.
  32. Lutkenhoff ES, McArthur DL, Hua X, Thompson PM, Vespa PM, Monti MM. Thalamic atrophy in antero-medial and dorsal nuclei correlates with six-month outcome after severe brain injury. *Neuroimage Clinics* 2013;3:396–404.
  33. Toyama Y, Kobayashi T, Nishiyama Y, Satoh K, Ohkawa M, Seki K. CT for acute stage of closed head injury. *Radiation Medicine* 2005;23:309–316.
  34. Rovegno M, Soto PA, Saez JC, von Bernhardt R. [Biological mechanisms involved in the spread of traumatic brain damage]. *Medicina Intensiva* 2012;36:37–44.
  35. Bruno MA, Majerus S, Boly M, Vanhaudenhuyse A, Schnakers C, Gosseries O, Boveroux P, Kirsch M, Demertzi A, Bernard C, et al. Functional neuroanatomy underlying the clinical subcategorization of minimally conscious state patients. *Journal of Neurology* 2012;259:1087–1098.
  36. Ashburner J, Friston KJ. Voxel-based morphometry—the methods. *Neuroimage* 2000;11:805–821.
  37. Good CD, Johnsrude IS, Ashburner J, Henson RN, Friston KJ, Frackowiak RS. A voxel-based morphometric study of ageing in 465 normal adult human brains. *Neuroimage* 2001;14:21–36.
  38. Graham DI, Maxwell WL, Adams JH, Jennett B. Novel aspects of the neuropathology of the vegetative state after blunt head injury. *Progress in Brain Research* 2005;150:445–455.
  39. Sato H, Tanaka T, Kasai K, Tanaka N. An autopsy case of acute carbon monoxide poisoning after a long-term vegetative state. *American Journal of Forensic Medicine & Pathology* 2012;33:341–343.
  40. Chu NS. Early and late CT manifestations in the persistent vegetative state due to cerebral anoxia-ischemia. *Journal of the Formosan Medical Association* 1993;92:697–701.
  41. Trivedi MA, Ward MA, Hess TM, Gale SD, Dempsey RJ, Rowley HA, Johnson SC. Longitudinal changes in global brain volume between 79 and 409 days after traumatic brain injury: relationship with duration of coma. *Journal of Neurotrauma* 2007;24:766–771.

42. Kozłowski Moreau O, Yollin E, Merlen E, Daveluy W, Rousseaux M. Lasting pituitary hormone deficiency after traumatic brain injury. *Journal of Neurotrauma* 2012;29:81–89.
43. Willie JT, Lim MM, Bennett RE, Azarion AA, Schwetye KE, Brody DL. Controlled cortical impact traumatic brain injury acutely disrupts wakefulness and extracellular orexin dynamics as determined by intracerebral microdialysis in mice. *Journal of Neurotrauma* 2012;29:1908–1921.
44. McAllister TW. Neuropsychiatric sequelae of head injuries. *Psychiatric Clinics of North America* 1992;15:395–413.
45. Soddu A, Vanhaudenhuyse A, Bahri MA, Bruno MA, Boly M, Demertzi A, Tshibanda JF, Phillips C, Stanziano M, Oviada-Caro S, et al. Identifying the default-mode component in spatial IC analyses of patients with disorders of consciousness. *Human Brain Mapping* 2012;33:778–796.
46. Giacino JT, Kalmar K, Whyte J. The JFK Coma Recovery Scale-Revised: measurement characteristics and diagnostic utility. *Archives of Physical Medicine & Rehabilitation* 2004;85:2020–2029.
47. Guldenmund P, Stender J, Heine L, Laureys S. Mindsight: diagnostics in disorders of consciousness. *Critical Care Research & Practice* 2012;2012:624724.
48. Seel RT, Sherer M, Whyte J, Katz DI, Giacino JT, Rosenbaum AM, Hammond FM, Kalmar K, Pape TL, Zafonte R, et al. Assessment scales for disorders of consciousness: evidence-based recommendations for clinical practice and research. *Archives of Physical Medicine & Rehabilitation* 2010;91:1795–1813.
49. Gitelman DR, Ashburner J, Friston KJ, Tyler LK, Price CJ. Voxel-based morphometry of herpes simplex encephalitis. *Neuroimage* 2001;13:623–631.
50. Salmond CH, Ashburner J, Vargha-Khadem F, Connelly A, Gadian DG, Friston KJ. Distributional assumptions in voxel-based morphometry. *Neuroimage* 2002;17:1027–1030.
51. Ashburner J. A fast diffeomorphic image registration algorithm. *Neuroimage* 2007;38:95–113.
52. Takahashi R, Ishii K, Miyamoto N, Yoshikawa T, Shimada K, Ohkawa S, Kakigi T, Yokoyama K. Measurement of gray and white matter atrophy in dementia with Lewy bodies using diffeomorphic anatomic registration through exponentiated lie algebra: a comparison with conventional voxel-based morphometry. *American Journal of Neuroradiology* 2010;31:1873–1878.
53. Peelle JE, Cusack R, Henson RN. Adjusting for global effects in voxel-based morphometry: gray matter decline in normal aging. *Neuroimage* 2012;60:1503–1516.
54. Manjon JV, Coupe P, Marti-Bonmati L, Collins DL, Robles M. Adaptive non-local means denoising of MR images with spatially varying noise levels. *Journal of Magnetic Resonance Imaging* 2010;31:192–203.
55. Rajapakse JC, Giedd JN, Rapoport JL. Statistical approach to segmentation of single-channel cerebral MR images. *IEEE Transactions on Medical Imaging* 1997;16:176–186.
56. Mikl M, Marecek R, Hlustik P, Pavlicova M, Drastich A, Chlebus P, Brazdil M, Krupa P. Effects of spatial smoothing on fMRI group inferences. *Magnetic Resonance Imaging* 2008;26:490–503.
57. Henley SM, Ridgway GR, Scahill RI, Kloppel S, Tabrizi SJ, Fox NC, Kassubek J. Pitfalls in the use of voxel-based morphometry as a biomarker: examples from huntington disease. *American Journal of Neuroradiology* 2010;31:711–719.
58. Weibull A, Gustavsson H, Mattsson S, Svensson J. Investigation of spatial resolution, partial volume effects and smoothing in functional MRI using artificial 3D time series. *Neuroimage* 2008;41:346–353.
59. Ho AK, Nestor PJ, Williams GB, Bradshaw JL, Sahakian BJ, Robbins TW, Barker RA. Pseudo-neglect in Huntington's disease correlates with decreased angular gyrus density. *Neuroreport* 2004;15:1061–1064.
60. Hellewell SC, Yan EB, Agyapomaa DA, Bye N, Morganti-Kossmann MC. Post-traumatic hypoxia exacerbates brain tissue damage: analysis of axonal injury and glial responses. *Journal of Neurotrauma* 2010;27:1997–2010.
61. Ekmark-Lewen S, Flygt J, Kiwanuka O, Meyerson BJ, Lewen A, Hillered L, Marklund N. Traumatic axonal injury in the mouse is accompanied by a dynamic inflammatory response, astroglial reactivity and complex behavioral changes. *Journal of Neuroinflammation* 2013;10:44.
62. Aldskogius H, Kozlova EN. Central neuron-glia and glial-glia interactions following axon injury. *Progress in Neurobiology* 1998;55:1–26.
63. Damoiseaux JS, Rombouts SA, Barkhof F, Scheltens P, Stam CJ, Smith SM, Beckmann CF. Consistent resting-state networks across healthy subjects. *Proceedings of the National Academy of Science USA* 2006;103:13848–13853.
64. Lieberman MD, Cunningham WA. Type I and Type II error concerns in fMRI research: re-balancing the scale. *Social Cognitive & Affective Neuroscience* 2009;4:423–428.
65. Ripolles P, Marco-Pallares J, de Diego-Balaguer R, Miro J, Falip M, Juncadella M, Rubio F, Rodriguez-Fornells A. Analysis of automated methods for spatial normalization of lesioned brains. *Neuroimage* 2012;60:1296–1306.
66. Karas GB, Scheltens P, Rombouts SA, Visser PJ, van Schijndel RA, Fox NC, Barkhof F. Global and local gray matter loss in mild cognitive impairment and Alzheimer's disease. *Neuroimage* 2004;23:708–716.
67. Genovese CR, Lazar NA, Nichols T. Thresholding of statistical maps in functional neuroimaging using the false discovery rate. *Neuroimage* 2002;15:870–878.
68. Nugent AC, Milham MP, Bain EE, Mah L, Cannon DM, Marrett S, Zarate CA, Pine DS, Price JL, Drevets WC. Cortical abnormalities in bipolar disorder investigated with MRI and voxel-based morphometry. *Neuroimage* 2006;30:485–497.
69. Deniz Can D, Richards T, Kuhl PK. Early gray-matter and white-matter concentration in infancy predict later language skills: a whole brain voxel-based morphometry study. *Brain & Language* 2013;124:34–44.
70. Braga B, Yasuda CL, Cendes F. White matter atrophy in patients with mesial temporal lobe epilepsy: voxel-based morphometry analysis of T1- and T2-Weighted MR Images. *Radiology Research & Practice* 2012;2012:481378.
71. Goldfine AM, Schiff ND. Consciousness: its neurobiology and the major classes of impairment. *Neurology Clinics* 2011;29:723–737.
72. Laureys S, Schiff ND. Coma and consciousness: paradigms (re) framed by neuroimaging. *Neuroimage* 2012;61:478–491.
73. Saleh A, Schroeter M, Jonkmanns C, Hartung HP, Modder U, Jander S. *In vivo* MRI of brain inflammation in human ischaemic stroke. *Brain* 2004;127:1670–1677.
74. Helmy A, Carpenter KL, Menon DK, Pickard JD, Hutchinson PJ. The cytokine response to human traumatic brain injury: temporal profiles and evidence for cerebral parenchymal production. *Journal of Cerebral Blood Flow & Metabolism* 2011;31:658–670.
75. Johnson VE, Stewart JE, Begbie FD, Trojanowski JQ, Smith DH, Stewart W. Inflammation and white matter degeneration persist for years after a single traumatic brain injury. *Brain* 2013;136:28–42.
76. Mura E, Pistoia F, Sara M, Sacco S, Carolei A, Govoni S. Pharmacological modulation of the state of awareness in patients with Disorders of Consciousness: an overview. *Current Pharmaceutical Design* 2014;20:4121–4139.
77. Gosseries O, Charland-Verville V, Thonnard M, Bodart O, Laureys S, Demertzi A. Amantadine, apomorphine and zolpidem in the treatment of disorders of consciousness. *Current Pharmaceutical Design* 2014;20:4167–4184.
78. Weiss N, Galanaud D, Carpentier A, Tezenas de Montcel S, Naccache L, Coriat P, Puybasset L. A combined clinical and MRI approach for outcome assessment of traumatic head injured comatose patients. *Journal of Neurology* 2008;255:217–223.
79. Scott SK. The neurobiology of speech perception and production—can functional imaging tell us anything we did not already know? *Journal of Communication Disorders* 2012;45:419–425.

80. Hattingen E, Blasel S, Nichtweiss M, Zanella FE, Weidauer S. MR imaging of midbrain pathologies. *Clinical Neuroradiology* 2010;20:81–97.
81. Hertz L. Bioenergetics of cerebral ischemia: a cellular perspective. *Neuropharmacology* 2008;55:289–309.
82. Lingor P, Koch JC, Tonges L, Bahr M. Axonal degeneration as a therapeutic target in the CNS. *Cell & Tissue Research* 2012;349:289–311.
83. Monti MM. Cognition in the vegetative state. *Annual Review of Clinical Psychology* 2012;8:431–454.
84. Giraud AL, Kell C, Thierfelder C, Sterzer P, Russ MO, Preibisch C, Kleinschmidt A. Contributions of sensory input, auditory search and verbal comprehension to cortical activity during speech processing. *Cerebral Cortex* 2004;14:247–255.
85. Soderfeldt B, Ingvar M, Ronnberg J, Eriksson L, Serrander M, Stone-Elander S. Signed and spoken language perception studied by positron emission tomography. *Neurology* 1997;49:82–87.
86. Vorobyev VA, Alho K, Medvedev SV, Pakhomov SV, Roudas MS, Rutkovskaya JM, Tervaniemi M, Van Zuijen TL, Naatanen R. Linguistic processing in visual and modality-nonspecific brain areas: PET recordings during selective attention. *Brain Research Cognitive Brain Research* 2004;20:309–322.