

# Impaired Effective Cortical Connectivity in Vegetative State: Preliminary Investigation Using PET

S. Laureys,<sup>\*,†</sup> S. Goldman,<sup>‡</sup> C. Phillips,<sup>†</sup> P. Van Bogaert,<sup>‡</sup> J. Aerts,<sup>†</sup> A. Luxen,<sup>†</sup> G. Franck,<sup>\*,†</sup> and P. Maquet<sup>\*,†</sup>

<sup>\*</sup>Department of Neurology, CHU Sart Tilman, and <sup>†</sup>Cyclotron Research Centre, University of Liège, 4000 Liège, Belgium; and <sup>‡</sup>PET/Biomedical Cyclotron Unit and Department of Neurology, ULB Erasme, Brussels, Belgium

Received July 10, 1998

**Vegetative state (VS) is a condition of abolished awareness with persistence of arousal. Awareness is part of consciousness, which itself is thought to represent an emergent property of cerebral neural networks. Our hypothesis was that part of the neural correlate underlying VS is an altered connectivity, especially between the associative cortices. We assessed regional cerebral glucose metabolism (rCMRGlu) and effective cortical connectivity in four patients in VS by means of statistical parametric mapping and [<sup>18</sup>F]fluorodeoxyglucose-positron emission tomography. Our data showed a common pattern of impaired rCMRGlu in the prefrontal, premotor, and parietotemporal association areas and posterior cingulate cortex/precuneus in VS. In a next step, we demonstrated that in VS patients various prefrontal and premotor areas have in common that they are less tightly connected with the posterior cingulate cortex than in normal controls. These results provide a strong argument for an alteration of cortical connectivity in VS patients.**

© 1999 Academic Press

## INTRODUCTION

Consciousness is thought to represent an emergent property of cortical and subcortical neural networks and their reciprocal projections. Its multifaceted aspects can be seen as expressions of various specialized areas of the cortex that are responsible for processing external and internal stimuli, short- and long-term storage, language comprehension and production, information integration and problem solving, and attention (Posner, 1994). Vegetative state (VS) is, by definition, a disorder of consciousness: arousal, sleep–wake cycles, ventilation, and autonomic control persist but external awareness (including all cognitive function and emotion) is abolished. The clinical diagnosis of VS can be made soon after a brain injury. It may be partially or totally reversible or it may progress to a persistent VS or death. *Persistent* VS is defined as a VS that persists

for at least 1 month after the acute brain injury (ANA Committee on Ethical Affairs, 1993; The Multi-Society Task Force on PVS, 1994).

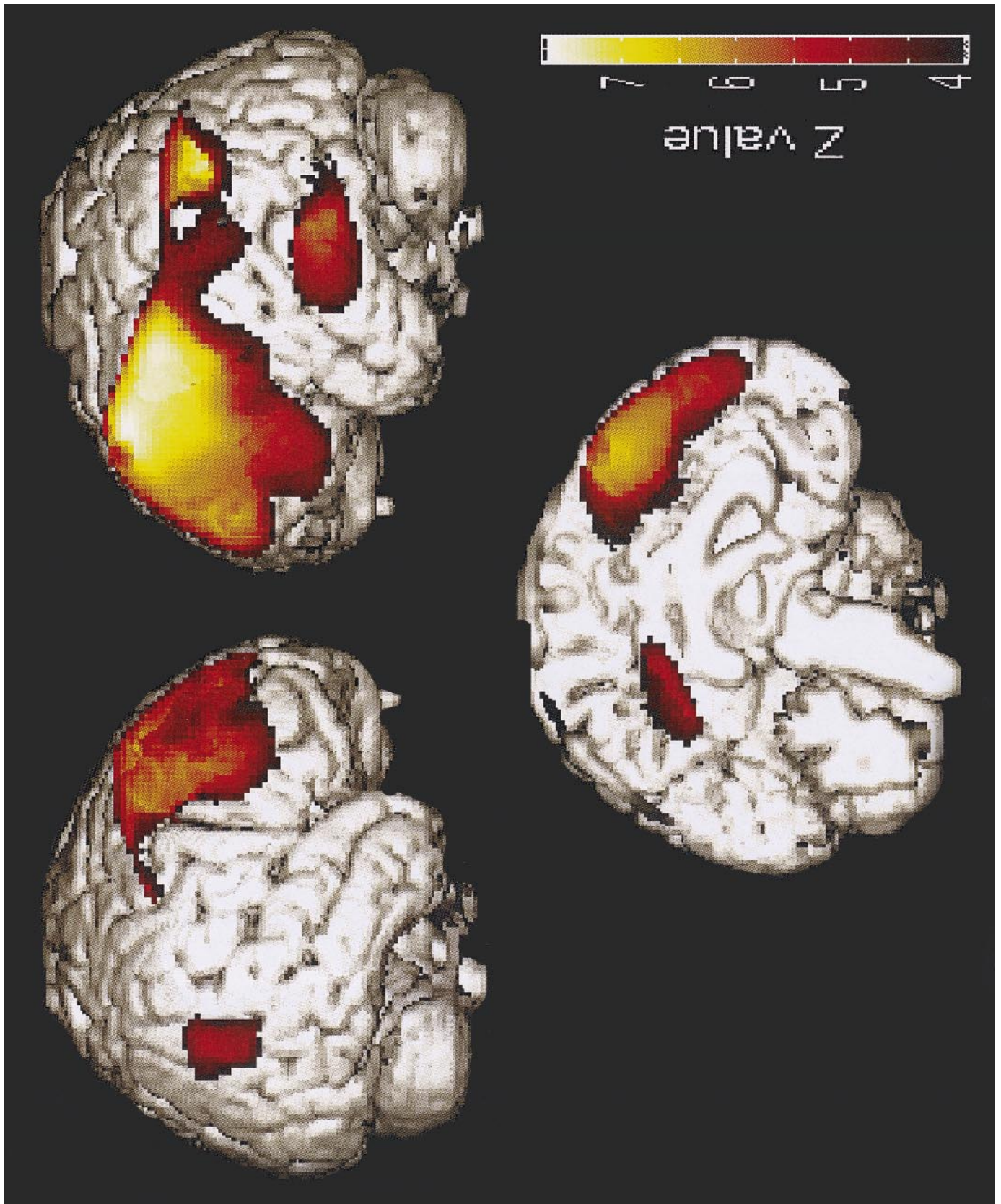
The underlying neuroanatomical basis of VS remains poorly understood. Neuropathological studies of patients in persistent VS of nontraumatic origin show widespread cortical damage with involvement of the association cortices in conjunction with the primary and secondary sensory cortices (Kinney and Samuels, 1994). Previous positron emission tomography (PET) studies, in patients in VS of diverse origin and duration, showed a reduction in metabolism of overall cortex (Levy *et al.*, 1987). On a regional basis, the most profound reduction in metabolic activity was found in the parietooccipital and mesiofrontal cortices in persistent VS of anoxic origin (De Volder *et al.*, 1990). In neither study was statistical parametric mapping analysis performed.

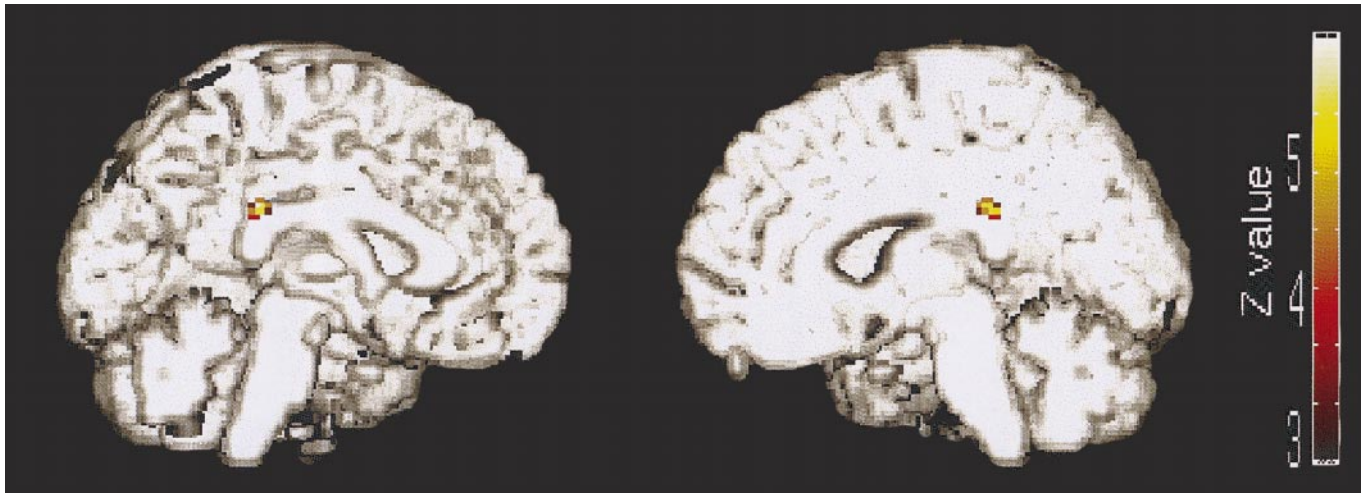
We tested the hypothesis that patients in VS, independent of the cause or duration of their condition, suffer from an altered connectivity between the associative cortices. Regional cerebral glucose metabolism distribution (rCMRGlu) was assessed in four cases of VS by means of statistical parametric mapping (SPM) and [<sup>18</sup>F]fluorodeoxyglucose (FDG)-PET. We first localized the common pattern of cortical metabolic impairment in our VS patients and then studied effective cortical connectivity (Friston *et al.*, 1993) in these patients compared to normal subjects. Given the small number of observations, this paper should be viewed as a preliminary record of ongoing research.

## MATERIALS AND METHODS

The study was approved by the Ethics Committee of the University of Liège. Informed consent was obtained for all control subjects. We retrospectively analyzed patients scanned on clinical demand.

All patients fulfilled the international criteria for VS: (1) spontaneous eye opening without evidence of awareness of the environment; (2) no evidence of reproducible





**FIG. 2.** Localization of voxels that showed impaired connectivity with the left prefrontal/premotor cortex (Brodmann areas 6, 8, 9, and 10; marked with an asterisk in Table 1) in patients in vegetative state compared to controls. SPM $|Z|$  thresholded at voxel and cluster level  $P < 0.05$  ( $Z > 4.25$ ) projected on a normalized MRI template.

voluntary behavioral responses to any stimuli; (3) no evidence of language comprehension or expression; (4) intermittent wakefulness and behaviorally assessed sleep–wake cycles; and (5) normal cardiorespiratory function and blood pressure control (ANA Committee on Ethical Affairs, 1993; The Multi-Society Task Force on PVS, 1994).

#### Patient 1

A 40-year old right-handed woman evolved to a vegetative state after a CO intoxication. She showed spontaneous eye opening and preserved pupillary, oculocephalic, corneal, and vestibuloocular reflexes. Brain magnetic resonance imaging (MRI) performed 14 days after the insult was normal. Electroencephalography (EEG) showed a 6-Hz basal activity with more pronounced slowing on the left parietal regions. Auditory evoked potentials (AEP) were normal. Somesthetic evoked potentials (SEP) of the median nerve showed normal latency and amplitude of P14 and N20 potentials without any late cortical components. FDG-PET was performed 15 days after the insult. After 19 days the patient regained consciousness and full autonomy. One year after the accident she showed a spastic gait with altered fine motor function, most prominent on the right, slurred speech, and minor short-term memory disturbances.

#### Patient 2

A 40-year old right-handed woman presented a cardiorespiratory arrest due to a severe bronchial asthma and

was resuscitated. She remained in a VS with spontaneous eye opening and preserved pupillary, oculocephalic, corneal, and vestibuloocular reflexes. Brain MRI performed 22 days after the insult showed bilateral hemorragic ischemic lesions in the basal ganglia. EEG showed a nearly isoelectric basal activity with diffuse low-amplitude 3-Hz activity. Visual evoked potentials were absent and AEP was normal. FDG-PET was performed 22 days after the insult. Six months after the accident the patient remained in a VS.

#### Patient 3

A 26-year-old woman was in VS since 5 years after a traumatic head injury. At examination, eyes were spontaneously open and corneal as well as oculocephalic reflexes were present. Spontaneous limb movements with left predominance were observed. Myotatic reflexes were increased and plantar responses were extensor. The following investigations were performed contemporary to FDG-PET: cranial MRI, showing severe corticosubcortical atrophy and a focal lesion in the pons; EEG, showing diffuse 5-Hz slow dysrhythmia; AEP, showing absence of wave V after left stimulation (suggesting a pontomesencephalic lesion); and SEP, showing abnormal responses after stimulation of median nerves (N20 potentials absent on the left side and delayed and broadened on the right side).

#### Patient 4

A 28-year-old woman was admitted in coma after a suicide attempt using insulin and benzodiazepines. A

**FIG. 1.** The common pattern of altered cerebral metabolism characterizing vegetative state patients. SPM $|Z|$  thresholded at voxel- and cluster-level-corrected  $P < 0.05$  ( $Z > 3.963$ ), normalized to the stereotaxic space of Talairach (Friston *et al.*, 1995a) and projected on a normalized MRI template.

CT scan performed 4 days after admission showed signs of diffuse cerebral edema. The patient's condition evolved to VS and FDG-PET was performed 1 month after admission. Other investigations included EEG, showing diffuse delta dysrhythmia, and evoked potentials, showing delayed and broadened cortical responses after stimulation of median nerves and optic nerves. The patient regained consciousness 2 weeks after the PET study. Six months after the cerebral insult she showed a spasticity of the left leg and echolalia alternated with periods of mutism and spatio-temporal disorientation. CT scan now showed diffuse corticosubcortical atrophy and bilateral pallidal lesions.

FDG-PET data of the four patients were retrospectively analyzed. Patients 1 and 2 were scanned on a Siemens CTI 951 scanner at the Cyclotron Research Centre of the University of Liege; patients 3 and 4 were scanned on a Siemens 953 scanner at the PET/Biomedical Cyclotron Unit of the Erasmus hospital of the Université Libre de Bruxelles. In both centers data were obtained approximately 15–20 mm above the canthomeatal line and in two-dimensional mode. A transmission scan was performed to allow a measured attenuation correction. Five to 10 mCi of FDG was injected intravenously.

PET data were analyzed using the statistical parametric mapping software (SPM96 version; Welcome Department of Cognitive Neurology, Institute of Neurology, London, UK) implemented in MATLAB (Mathworks Inc., Sherborn, MA). The use of SPM to assess intersubject (rather than intrasubject) variability is unlikely to alter the relevance of our results given their high degree of significance. Data from each subject were normalized to a standard stereotactic space and then smoothed with a 16-mm full-width half-maximum isotropic kernel (Friston *et al.*, 1995a).

The control population was age matched and consisted of drug-free, healthy volunteers of both sexes ( $n = 53$ , mean age  $42 \pm 21$  years for patients 1 and 2; and  $n = 25$ , mean age  $27 \pm 9$  years for patients 3 and 4).

The design matrix included the four patient's scans and the 53 and 25 control subject's scans of both PET centers. Global flow normalization was performed by proportional scaling. The analysis identified brain regions where glucose metabolism was significantly lower in the patient than in the respective center-defined control group. The resulting set of voxel values for each contrast, constituting a map of the  $t$  statistics [SPM( $t$ )], was transformed to the unit normal distribution SPM( $Z$ ) and thresholded at  $P < 0.001$  ( $Z = 3.09$ ). The resulting foci were characterized in terms of peak height over the entire volume analyzed at a threshold of voxel-level-corrected  $P < 0.05$  (Friston *et al.*, 1995b). A conjunction

analysis provided the common pattern in rCMRglu decreases characterizing our four VS patients.

In a second step, we used a psychophysiological interaction analysis to test the hypothesis on altered effective cortical connectivity in VS compared to normals (Friston *et al.*, 1993). The design matrix included the same scans as described above and took into account group differences in mean levels of glucose consumption. Now the analysis looked for brain regions that experienced a significant difference in reciprocal modulation with/from the cortical regions most attained in VS. It included the most significant peaks of the 16 different Brodmann area's (voxel level corrected  $P < 0.05$ ) obtained from the first analysis and assessed the difference in modulation of every of these 16 voxels depending on the condition patient or normal control. Results were significant at voxel-level-corrected  $P < 0.05$  ( $Z \geq 3.96$ ).

## RESULTS

A common pattern of significantly impaired rCMRglu in the four VS patients was observed in the left and right middle and superior frontal gyri, the left inferior frontal gyrus, the left inferior parietal lobule, the left middle temporal gyrus, the right superior temporal gyrus, the posterior cingulate cortex/precuneus, and the left pre- and postcentral gyri (Fig. 1 and Table 1).

We observed a significant difference in effective connectivity between the most significant voxels of the left prefrontal and premotor cortex (BA 6, 8, 9, 10; marked with an asterisk in Table 1) and the posterior cingulate cortex (BA 23/31;  $x = 2$ ,  $y = -32$ ,  $z = 28$ ;  $Z$ score 4.66;  $P$  corrected = 0.01) in patients in VS compared to controls (Fig. 2). No such result was obtained with right-sided anterior areas.

## DISCUSSION

At the time of PET scanning all patients were in a VS according to the international criteria (ANA Committee on Ethical Affairs, 1993; The Multi-Society Task Force on PVS, 1994). It is important to distinguish between VS and *persistent* VS, the latter being defined as a VS that has continued or endured for at least 1 month. In the present study, we were interested in the impairments of effective cortical connectivity in VS independent of its duration, outcome, or cause. Patients 1 and 4 recovered from their VS; patients 2 and 3 failed to recover. The etiology of their condition was different for each case (toxic, anoxic, posttraumatic, and metabolic).

The presented data show a significant dysfunction of the prefrontal, premotor, and parietotemporal association areas and posterior cingulate cortex/precuneus as the common neural correlate in our VS patients. The observed pattern of metabolic impairment is in agree-

TABLE 1

Statistical Results and Localization of the Most Significant Voxels Where rCMRglu Is Decreased in Patients in Vegetative State Compared to Their Respective Control Population (Voxel-Level-Corrected  $P < 0.05$ )

Area (Brodmann's area)	x	y	z	Z score	P (corrected)	
<b>Left middle frontal gyrus*</b>	<b>(6)</b>	<b>-32</b>	<b>26</b>	<b>56</b>	<b>8.29</b>	<b>&lt;0.001</b>
Left middle temporal gyrus	(39)	-50	-62	30	7.43	<0.001
<b>Left middle frontal gyrus*</b>	<b>(8)</b>	<b>-36</b>	<b>14</b>	<b>40</b>	<b>7.01</b>	<b>&lt;0.001</b>
Left postcentral gyrus	(2)	-44	24	42	6.90	<0.001
Left inferior parietal lobule	(40)	-64	-34	36	6.13	<0.001
Left middle temporal gyrus	(21)	-66	-44	-6	6.12	<0.001
<b>Left superior frontal gyrus*</b>	<b>(9)</b>	<b>-16</b>	<b>56</b>	<b>26</b>	<b>5.57</b>	<b>&lt;0.001</b>
Left inferior frontal gyrus	(45)	-56	34	0	5.56	<0.001
<b>Left middle frontal gyrus*</b>	<b>(10)</b>	<b>-28</b>	<b>56</b>	<b>20</b>	<b>5.52</b>	<b>&lt;0.001</b>
Left posterior cingulate gyrus	(31)	-2	-40	36	4.88	0.001
Left inferior temporal gyrus	(37)	-62	-60	-8	4.53	0.006
Right superior frontal gyrus	(8)	14	38	52	7.18	<0.001
Right middle frontal gyrus	(46)	46	32	30	5.44	<0.001
Right superior frontal gyrus	(10)	30	52	24	4.51	0.006
Right superior temporal gyrus	(22)	48	-56	16	4.50	0.007
Right middle frontal gyrus	(6)	42	12	54	4.41	0.010

Note. All the voxels were included in the statistical model assessing effective cortical connectivity. Voxels where the sum of activity differentially predicts the activity in posterior cingulate cortex/precuneus are marked with an asterisk. Coordinates are defined in the stereotaxic space of Talairach (Friston *et al.*, 1995a).

ment with postmortem findings in persistent VS where involvement of the association cortices is reported as critical neuroanatomic substrate (Kinney and Samuels, 1994).

Furthermore, we observed that the left-sided anterior regions differently modulate the posterior cingulate cortex in VS patients compared to controls. Numerous neuropsychological studies in nonhuman primates suggest the role of the posterior cingulate cortex in spatial orientation and memory (Vogt *et al.*, 1992). In addition, clinical studies have implicated the posterior cingulate cortex in anterograde and retrograde amnesia in humans (Valenstein *et al.*, 1987; Rudge and Warrington, 1993). Functional imaging studies have shown activation of the retrosplenial region (encompass-

ing the posterior cingulate gyrus and the precuneus) in episodic verbal memory retrieval (Shallice *et al.*, 1994), modulation of visual perception by attention (Dolan *et al.*, 1997), and mental imagery (Fletcher *et al.*, 1995). Interestingly, the posterior cingulate cortex is one of the most active cerebral regions in conscious waking (Andreasen *et al.*, 1995; Maquet *et al.*, 1997) and is systematically one of the least active regions in unconscious or minimally conscious states such as slow-wave sleep and rapid eye movement sleep (Maquet *et al.*, 1996, 1997). These arguments suggest that the posterior cingulate cortex might represent part of the neural network subserving conscious experience.

The choice of the anterior regions included in the psychophysiological interaction analysis was dictated by the current knowledge about cortical afferents to the posterior cingulate cortex in mammals. The posterior cingulate cortex of rats, cats, and monkeys is linked by direct neural pathways both to areas with known sensory and motor functions and to areas affiliated with the limbic system. Neuroanatomical tracer studies have shown projections to the posterior cingulate cortex from the prefrontal cortex (areas 9 and 10) and from the premotor areas (area 6 and 8) (Bates and Goldman-Rakic, 1993; Olson and Musil, 1992; Pandya *et al.*, 1981).

As our statistical model included influences from not one but all 16 regions that showed decreased CMRglu in VS, the observed inferences about the psychophysiological interactions are valid in relation to effective connectivity as defined by Friston *et al.* (1997). It seems that the sum of activity in the left prefrontal and premotor regions differentially predicts activity in the posterior cingulate cortex between the four examined patients in VS and their control population. This is in accordance with experiments in nonhuman primates where the functional integrity of the prefrontal cortex and its interactions with modality-specific posterior brain regions is considered critically dependant for working memory (Goldman-Rakic, 1988).

No significant impairment in effective connectivity was observed for the right frontal cortex nor for the posterior cortices (BA 39, 40). Neither was any significant loss of effective connectivity observed for the overall cortex from subcortical nuclei (e.g., the thalamus) (Kinney *et al.*, 1994). This negative result might be due to the small number of patients studied and to the heterogeneity of the lesions. Further observations are needed to investigate the respective role of other neural circuitry involving more cortical and subcortical (thalamic) structures underlying VS.

This report provides the first and preliminary argument suggesting a disturbed connectivity between distal cerebral areas in VS patients.

## ACKNOWLEDGEMENTS

We thank Dr. S. Giurgiu for providing the clinical data of patient 3. This research was supported by FNRS Grant 3.4571.97 and by the Queen Elisabeth Medical Foundation.

## REFERENCES

- ANA Committee on Ethical Affairs. 1993. Persistent vegetative state: Report of the American Neurological Association Committee on Ethical Affairs. ANA Committee on Ethical Affairs. *Ann. Neurol.* **33**:386–390.
- Andreasen, N. C., O'Leary, D. S., Cizadlo, T., Arndt, S., Rezaei, K., Watkins, G. L., Ponto, L. L., and Hichwa, R. D. 1995. Remembering the past: Two facets of episodic memory explored with positron emission tomography. *Am. J. Psychiatry* **152**:1576–1585.
- Bates, J. F., and Goldman-Rakic, P. S. 1993. Prefrontal connections of medial motor areas in the rhesus monkey. *J. Comp. Neurol.* **336**:211–228.
- De Volder, A. G., Goffinet, A. M., Bol, A., Michel, C., de, B. T., and Laterre, C. 1990. Brain glucose metabolism in postanoxic syndrome: Positron emission tomographic study. *Arch. Neurol.* **47**:197–204.
- Dolan, R. J., Fink, G. R., Rolls, E., Booth, M., Holmes, A., Frackowiak, R. S., and Friston, K. J. 1997. How the brain learns to see objects and faces in an impoverished context. *Nature* **389**:596–599.
- Fletcher, P. C., Frith, C. D., Baker, S. C., Shallice, T., Frackowiak, R. S., and Dolan, R. J. 1995. The mind's eye-precuneus activation in memory-related imagery. *NeuroImage* **2**:195–200.
- Friston, K., Ashburner, J., Frith, C., Poline, J. B., Heather, J., and Frackowiak, R. S. J. 1995a. Spatial realignment and normalization of images. *Human Brain Mapping* **2**:165–189.
- Friston, K., Holmes, A. P., Worsley, K. J., Poline, J. B., Frith, C. D., and Frackowiak, R. S. J. 1995b. Statistical parametric maps in functional imaging: A general approach. *Hum. Brain Map.* **2**:189–210.
- Friston, K. J., Buechel, C., Fink, G. R., Morris, J., Rolls, E., and Dolan, R. J. 1997. Psychophysiological and modulatory interactions in neuroimaging. *NeuroImage* **6**:218–229.
- Friston, K. J., Frith, C. D., Liddle, P. F., and Frackowiak, R. S. J. 1993. Functional connectivity: The principal component analysis of large (PET) data sets. *J. Cereb. Blood Flow Metab.* **13**:5–14.
- Goldman-Rakic, P. S. 1988. Topography of cognition: Parallel distributed networks in primate association cortex. *Annu. Rev. Neurosci.* **11**:137–156.
- Kinney, H. C., Korein, J., Panigrahy, A., Dikkes, P., and Goode, R. 1994. Neuropathological findings in the brain of Karen Ann Quinlan—The role of the thalamus in the persistent vegetative state. *N. Engl. J. Med.* **330**:1469–1475.
- Kinney, H. C., and Samuels, M. A. 1994. Neuropathology of the persistent vegetative state: A review. *J. Neuropathol. Exp. Neurol.* **53**:548–558.
- Levy, D. E., Sidtis, J. J., Rottenberg, D. A., Jarden, J. O., Strother, S. C., Dhawan, V., Ginos, J. Z., Tramo, M. J., Evans, A. C., and Plum, F. 1987. Differences in cerebral blood flow and glucose utilization in vegetative versus locked-in patients. *Ann. Neurol.* **22**:673–682.
- Maquet, P., Degueldre, C., Delfiore, G., Aerts, J., Peters, J. M., Luxen, A., and Franck, G. 1997. Functional neuroanatomy of human slow wave sleep. *J. Neurosci.* **17**:2807–2812.
- Maquet, P., Peters, J., Aerts, J., Delfiore, G., Degueldre, C., Luxen, A., and Franck, G. 1996. Functional neuroanatomy of human rapid-eye-movement sleep and dreaming. *Nature* **383**:163–166.
- Olson, C. R., and Musil, S. Y. 1992. Topographic organization of cortical and subcortical projections to posterior cingulate cortex in the cat: Evidence for somatic, ocular, and complex subregions. *J. Comp. Neurol.* **324**:237–260.
- Pandya, D. N., Van, H. G., and Mesulam, M. M. 1981. Efferent connections of the cingulate gyrus in the rhesus monkey. *Exp. Brain Res.* **42**:319–330.
- Posner, M. I. 1994. Attention: The mechanisms of consciousness. *Proc. Natl. Acad. Sci. USA* **91**:7398–7403.
- Rudge, P., and Warrington, F. 1993. Selective impairment of memory and visual perception in splenial tumors. *Brain* **114**:349–360.
- Shallice, T., Fletcher, P. C., Frith, C. D., Grasby, P., Frackowiak, R. S. J., and Dolan, R. J. 1994. Brain regions associated with acquisition and retrieval of verbal episodic memory. *Nature* **368**:633–635.
- The Multi-Society Task Force on PVS 1994. Medical aspects of the persistent vegetative state (1). *N. Engl. J. Med.* **330**:1499–1508.
- Valenstein, E., Bowers, D., Verfaillie, M., Heilman, K. M., Day, A., and Watson, R. T. 1987. Retrosplenial amnesia. *Brain* **110**:1631–1646.
- Vogt, B. A., Finch, D. M., and Olson, C. R. 1992. Functional heterogeneity in cingulate cortex: The anterior executive and posterior evaluative regions. *Cereb. Cortex* **2**:435–443.